

Effect of Hydroalcoholic Extract of Henna (*Lawsonia inermis*) on Liver Enzymes and Development in Neonatal Male Rats Born from Treated Mothers

Goodarzi Farahnaz¹, Shariati Mehrdad², Mahjoor Amir Ashkan³

^{1,2}Department of Biology, Kazerun Branch, Islamic Azad University, Kazerun, Iran

³ Department of Veterinary, Kazerun Branch, Islamic Azad University, Kazerun, Iran

Received: May 16, 2014

Accepted: August 9, 2014

ABSTRACT

Introduction and purpose: Considering the important role of the liver in relation to metabolism of chemical composition and plasma protein synthesis and also excessive use of herbs (medicinal plants) in traditional medicine, particularly Henna; current study was conducted with purpose of investigating the effects of hydroalcoholic extracts of henna on the activity of liver enzymes and blood biochemical factors and development of neonatal male mouse liver.

Material and methods: In this experimental study, 40 male Wistar rat were participated, they were divided into 5 groups of 8 mothers who had previously received specific doses of 100, 200, 400 mg of the henna extract during their pregnancy and in experimental groups 1, 2 and 3 respectively. After the end of 22 days neonatal period, the rats were weighed and assessment of liver enzymes, albumin and protein were performed. Histological examination was performed after preprocessing through the steps of slicing, smears and staining with hematoxylin - eosin.

Results: The hydroalcoholic extracts of henna caused significant increase in liver enzymes including ALP, AST, ALT and protein, this increase is dose-dependent and was observed in the treatment groups than in the control group ($p < 0.05$). However, other variables such as infants birth weight, liver weight, and albumin level was not significant in the treatment groups than control group. There was mild, moderate or severe pathologic changes in liver of groups whom receiving henna extract.

Conclusion: Results of enzyme tests and histopathological changes in liver shown that hydroalcoholic extracts of henna cause damage in newborn mice liver and suggesting that this herb should be used with caution during pregnancy, although more study is needed in this area.

KEYWORDS: hydroalcoholic extracts of henna, liver function tests, male desert rat's infant

INTRODUCTION

Different studies shown that women tend to use more botanical drugs, and frequently used them for relieve of problems like dysmenorrhea, minimizing menopause symptoms, menstrual disorders, prevention of osteoporosis and also pregnancy related problems. Pregnant women also assumes that natural remedies are not problematic and do not lead to complications for the mother and the fetus; so they attempt to cure pregnancy related problems with herbal ingredients [1].

Henna or arghan (*Lawsonia inermis*) is a tall shrub or small tree form myrtales order and lythraceae family, standing about 5-6 meter tall. The leaves are glabrous, lanceolate, oval, and grows opposite each other on the stem, with 2-3 cm length and flowers are fragrant, white, and paired [30]. The medicinal part of the plant is its leaves [3]. The henna plant is native to tropical regions of Africa and Asia. It is cultivated in Kerman, Hormozgan, and Baloochestan province of Iran [4]. Henna leaves contain a pigment called Lawson or 2-hydroxy-1, 4- naphthoquinone (1-1.4%), flavonoids such as apigenin, luteolin, quercetin, several phenolic glycosides, coumarin, xanthone, quinoids, glycosides, beta-cytostrol, terpenoids, 6% lipid, 2-3% resin, 7-8% tannin, catechin and 1.2% essence. Other compounds derived from henna leaves are 5-7 glycosides derivatives, gallic acid, acastin glycoside, 1,4- naphthoquinone, laxanthon 1 and 2, and small amount of alkaloids [5]. There are mannitol and mucilage in henna in addition to above components [6]. Henna leaves have hemolysis capacity due to a compound called lawsone with chemical name of 2- hydroxy-1, 4- naphthoquinone which has oxidation property [7]. It is used topically for the treatment of fungal disease and rheumatoid pain. It is also used as pigment especially for coloring skin and hair [8]. The leaves have narcotic effects and high doses led to headache and poisoning [9].

Hana has antioxidant and regenerative properties as well as neutralizing the free radicals [10]. Henna leaf extract has antioxidant and immunomodulatory (immune modulation) activities [12]. It also has a protective effect in preventing protein oxidation and glycolisation [13].

*Corresponding Author: Dr. Mehrdad Shariati, Islamic Azad University, Kazerun Branch, Iran
E.mail: mehrdadshariati@kau.ac.ir

In traditional medicine, henna has been used for treating joint pains, rash and sores. It and has been used as a coloring agent for hair and skin too [15]. Lawson temporarily slowing the heart rate and increased the amplitude of heart muscle contraction. Anti-diarrheal effect of Lawson is due to lowering the tone and peristalsis of the intestines [16]. Lawson has been shown anti-inflammatory, analgesic and antipyretic effects with dose of 500 mg/kg [17].

The liver is the largest gland in the body and second largest organ in the body after skin. It is modified variety of foreign substances and results of body metabolism and compounds such as ammonia and various hormones; also liver is a storage place for various materials such as triglycerides, vitamins and sugar and the main place of gluconeogenesis [18]. Hepatic enzymes are involved in the processes of detoxification and inactivation various materials and toxins through bio-transformation procedures. One of the indicative tests for liver function condition is measurement of transaminase, which is responsible for transfer of amino group between aspartate and alanine to alpha - Ketoglutarat. Every qualitative and quantitative changes in various hepatic enzymes is reflecting the health or disease state of liver and a representation of the severity of liver necrosis [19]. The most sensitive and the most widely used hepatic enzymes are the aminotransferases, including aspartate aminotransferase (AST) and alanine aminotransferase (ALT). ALT is an aminotransferases enzymes that transfer amine group and catalyze conversion of alpha ketoacid to the amino acid [20]. Combination of oxaloacetate and alanine and production of glutamate and pyruvate which is a duplex reaction, catalyzed by the ALT and provide a more specific and sensitive indicator in the assessment of liver function enzymes than AST [21]. Liver damage would lead to increased leakage of ALT and AST from the hepatocyte into the blood stream. ALP raises in pathological conditions and the liver and bone disorders. Thus, the blood level of this enzyme is one of the health indicators of the liver [22].

Studies have shown that the methanol extract of the roots of henna has abortion inducing effects [23]. And there are reports indicating that, henna parboil is used to induce abortion in pregnancy [24]. But so far, the effects of this herb during pregnancy has not been studied on the baby's liver scientifically. Therefore, present study was conducted with main purpose of assessing the effects of the henna plant on liver enzymes and some blood biochemical factors and also changes in liver tissue of male newborn rats.

MATERIAL AND METHODS

Sampling and required equipment

Animals used in this study consisted of 40 male newborn rats of the Wistar genus, weighing approximately 100 g and 22 days old. Their mothers were under care in the animal infirmary of the Islamic Azad University, Kazerun Branch, and henna extract has been prescribed to them during pregnancy, the male pups were separated from their mothers after birth and have been kept at the same center. Animals were kept at fixed ambient temperature of $22 \pm 2^\circ\text{C}$ and fixed photoperiod of 12 h darkness and 12 hours light. Indirect and consistent light was come through the windows. Animals were held in polycarbonate cages with $40 \times 25 \times 15$ cm dimensions with steel grid ceiling. Cage floor was carpeted by wood chips. Air conditioning system in the laboratory was active and in good condition. Mice drink water from municipal tap water and their mothers were feed by compressed rat food supplied by Pars cooperative company of livestock and poultry feed, newborn was fed by breast milk. Liver enzymes measuring kits were purchased from Pars Azemoun in Iran.

Extract preparation method

Henna leaves have been collected from Yazd surroundings, then dried in the sun for one week and extraction was performed using maceration technique. 100 g of plants powder was mixed in 1000 ml solvent (ethanol 70%) and after 48 h sleep at 37°C , the resulting solution was filtered through Watman no.1 filter paper. The filtered solution was converted to extract powder through using a rotating evaporation device (Rotary) and under vacuum conditions. It should be noted that alcoholic content of the solution would be evaporated and has no impact on the results of the experiment. Then dry powder kept in the refrigerator for later use. In the day of experiment, fresh solution of 100, 200 and 400 mg/kg were prepared and used [27, 28].

Procedure

In this experimental study, 40 head of the baby Wistar rats were divided into 5 groups of 8 heads, and each kept in the separate cage but same condition. The control group consisted of 8 male infants of mothers who have spent a normal and extract free course of pregnancy. The placebo group was consisted of 8 male infants who born from mothers with normal pregnancy and daily dose of 0.3 ml solvent (distilled water). There was three treatment groups consisted of 8 male infant each, who born from mothers of treatment groups 1, 2, 3 who received 100, 200, 400 mg/kg henna extract, respectively. The LD50 of henna was 2000 mg/kg and intra peritoneal injection of extract for 21 day were used as study intervention on treatment groups [25]. After birth and at the end of the 22-days of neonatal period, blood samples have been collected from all the groups. Sampling was done from the heart. Tubes containing blood were centrifuged for 15 minutes at a speed of 5000 RPM, then serum aliquot was separated and kept at -20°C until enzymatic assays. For measurement of the enzymes level of activity, samples were transferred to the lab, then tested using the enzyme assay kits from the Pars Azemoun, Iran and also with the help of the US made Technicon RA -1000 device. After collection of

blood samples, animal's liver were dissected and fixed in 10% formalin solution, and after passing the stages of the slicing and staining, tissue slides were prepared [26].

Statistical analysis

Data collected throughout the study was analyzed by SPSS Ver. 20 software package using comparison of means and variance analysis tests. $P \leq 0.05$ was considered statistically significant.

RESULTS

The study results shown that there was not any significant statistical differences between two groups of control and placebo. Comparison of the results related to the ALT, AST and ALP enzyme in 100, 200, 400 mg/kg groups shown a significant increases than control group.

The amount of serum protein in groups receiving a dose of 200 and 400 mg/kg have significant increases than control group. There was not any significant change in other variables compared with control group (Table 1 and 2).

Table 1. The plasma level of hepatic enzymes (U/L) in different groups

Groups	ALT	AST	ALP
Control	92.87 \pm 6.91	360.50 \pm 38.32	600.37 \pm 26.92
Placebo	76.575 \pm 17.71	424.83 \pm 63.22	602.50 \pm 95.85
Treatment 1 100 mg/kg	121.85 \pm 10.15*	500.42 \pm 158.19*	750.85 \pm 53.05*
Treatment 2 200 mg/kg	148.075 \pm 17.90*	518.00 \pm 67.91*	899.00 \pm 50.81*
Treatment 3 400 mg/kg	150.00 \pm 6.67*	621.25 \pm 45.68*	963.37 \pm 44.75*

* There was significant difference with control group ($p \leq 0.05$)

Table 2. Some biochemical factors in blood (Albumin, Protein), liver weight and infant weight

Groups	Infant Weight (g)	Liver Weight (g)	Albumin (mg/dl)	Protein (mg/dl)
Control	73.33 \pm 1.84	3.90 \pm 0.19	3.42 \pm 0.05	5.95 \pm 0.15
Placebo	79.55 \pm 3.48	4.57 \pm 0.38	3.55 \pm 0.06	5.60 \pm 0.04
Treatment 1 100 mg/kg	72.20 \pm 3.39	3.95 \pm 0.40	3.58 \pm 0.01	6.22 \pm 0.10
Treatment 2 200 mg/kg	87.75 \pm 7.31	3.60 \pm 0.41	3.42 \pm 0.09	6.71 \pm 0.18*
Treatment 3 400 mg/kg	87.66 \pm 7.05	3.76 \pm 0.27	3.57 \pm 0.05	6.83 \pm 0.24*

Results of histologic studies

In this research study, in histological studies on the liver paranchymal cells, it was observed that the liver paranchymal cells were normal in both control and placebo group. Comparing liver paranchymal cells in different treatment group who received the extract (100, 200 and 400 mg/kg) with control group, the rate of necrosis was higher in the treatment groups than control group with progressive increase corresponding with the consumed extract dose (Figs. 1-5, respectively). It can be said that the amount of liver tissue necrosis increase is consistent with dose increases.

There was large number of binuclear cells and picnotic bodies in the sinusoids, large number of degenerated macrophages and red blood cells in the liver of treatment groups who received extract. Moreover, basophil levels in the cytoplasm of groups who received the extract was higher than the control and placebo group.

Figure 1 - Photomicrograph of liver tissue in control group - the longitudinal sections with hematoxylin - eosin staining, 20x magnification; all hepatocytes are healthy.

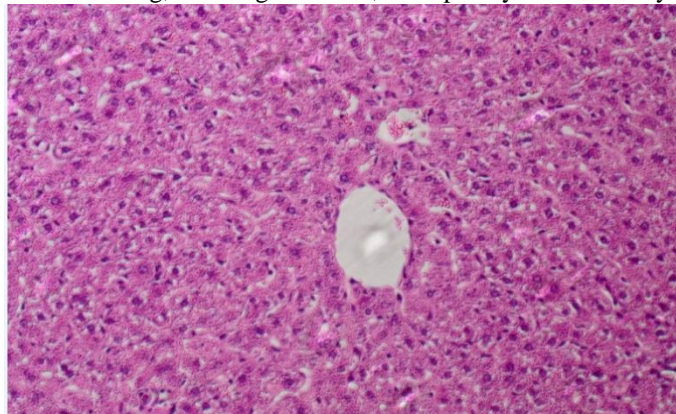


Figure 2 - Photomicrograph of liver tissue in treatment group - the longitudinal sections with hematoxylin - eosin staining, 20x magnification; all hepatocytes are healthy.

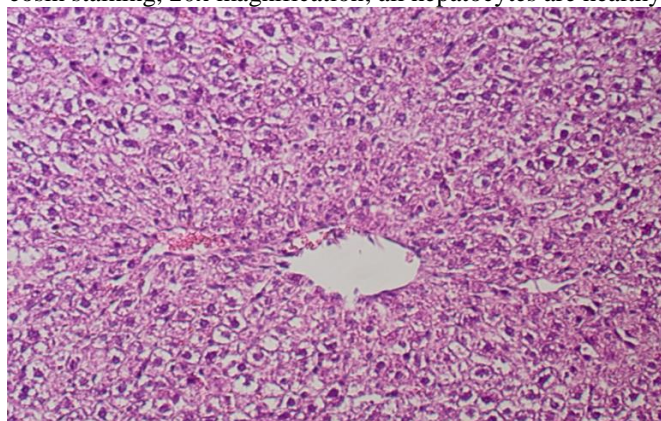


Figure 3 - Photomicrograph of liver tissue in treatment group 1 - the longitudinal sections with hematoxylin - eosin staining, 20x magnification; arrow shows the necrotic tissue.

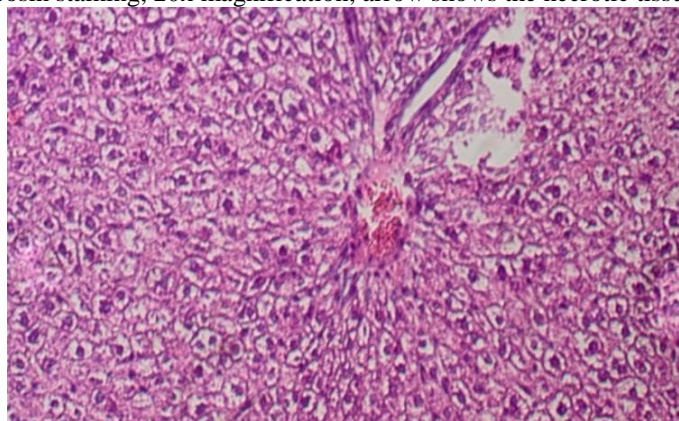
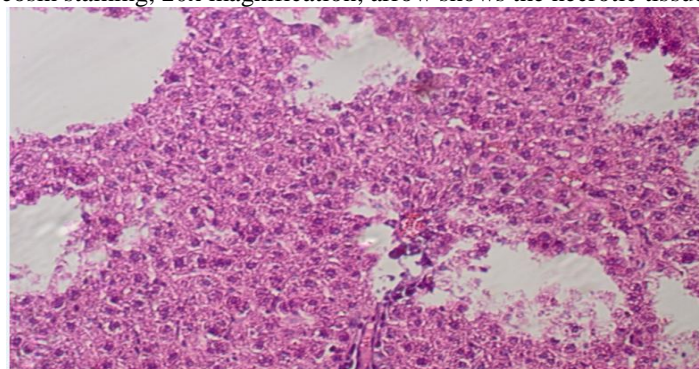


Figure 4 - Photomicrograph of liver tissue in treatment group 2 - the longitudinal sections with hematoxylin - eosin staining, 20x magnification; arrow shows the necrotic tissue.

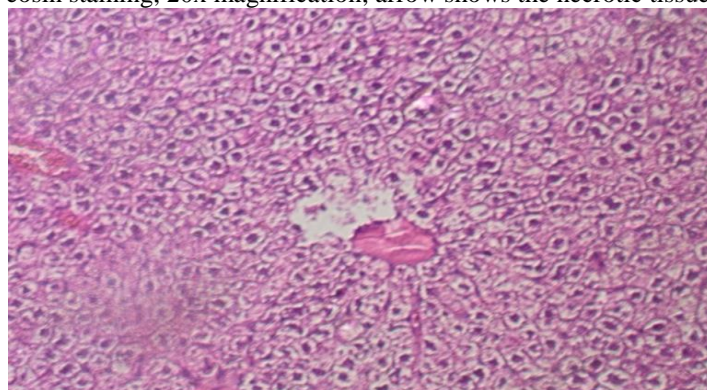

Figure 5 - Photomicrograph of liver tissue in treatment group 3 - the longitudinal sections with hematoxylin - eosin staining, 20x magnification; arrow shows the necrotic tissue.



DISCUSSION

According to tissue studies, considering high number of binuclear cells in the liver of treatment groups, and extreme abnormal nuclear divisions; it was clear that henna extract has teratogenic effects on liver tissue. Previous studies have shown that wild tea has teratogenic effects due to the presence of two compounds called apigenin and alpha-pinene [29]. On the other hand, it has also been shown that henna extract contain large amounts of apigenin [39]. There is also a high rate of pyknotic bodies in the sinusoids, and relatively large numbers of degenerated macrophages and red blood cells which proved the presence of hemolysis due to the henna effects. 2-hydroxy-1, 4-naphthoquinone (Lawson) found in henna extract could induce hemolysis due to its oxidant properties. This material is metabolized in the liver and convert to a toxic metabolite, which crosses the placenta and influences the sensitive period of organogenesis and embryonic development [7, 31]. Liver enzymes Such as ALT AST and ALP are enzymes that specifically reflect necrosis of hepatocytes and cholestasis, and are used frequently in diagnosis of severe liver disease [32, 33]. Dog, cat, rabbit and rat ALT was specific to cytosol of hepatocytes, which is increase in blood plasma following changes in liver function [34]. In addition, AST has been suggested for diagnosing liver failure [34]. ALP is a glycoprotein attached to the membrane, which is found in various tissues such as liver, bone and lesser in kidney, intestine and placenta; and it is a worthy biochemical markers in diagnosis of osteoporosis and disorders of the liver, bile and fatty liver disease [35, 36]. In the current study, ALT, AST and ALP levels have shown a significant increases in the treatment groups than control group.

Mohamed A. and his colleagues studies showed that the aqueous extract of the seeds of henna increased liver enzymes and necrosis of hepatocytes in mice, and these changes are attributed to addition of the henna pigment (Lawson) to other henna's compounds (flavonoids and terpenoids), but no specific mechanism was studied in this study [37].

In a research study on a species of the genus *Satureja* (savory) called *Macrantha*, the toxicity caused by this type of plant was attributed to terpenoid compounds especially triterpenes, which possesses strong toxic effects [38]. So we can conclude that at least one of the factors that are likely to cause toxic effects of henna in our study can be terpenoid compounds.

Research has shown that methanolic extracts of henna root cause repeated abortion in mice, rats and guinea pigs, and this effect was attributed to the most existing composition in hydro alcoholic extract, apigenin [39]. It also has been shown that apigenin metabolism is quite slow, and the slow uptake and excretion phase of this material could lead to flavonoid accumulation in the body [40].

Histopathological changes in the liver tissue of groups treated by henna extract showed that presence of hepatic necrosis may be due to effects of apigenin in occurrence of apoptosis. apigenin increase reactive oxygen species, cytochrome C production and release from mitochondria into the cytosol, and consequently, cause processing and subsequent induction of pro-caspase 9 and finally apoptosis through induction of caspase 3 activity and rapid reduction of trans-membrane potential [41].

Although antioxidant activity of chemical compounds of plants is well known [42], but under certain conditions, such as high doses or in the presence of metal ions can exhibit the peroxidant activity, this peroxidant activity or antioxidant compounds of plants have closed relationship with its prescribed concentration [43], which consistent with liver pathological lesions observed in our study.

However, studies on cellular models have shown that many antioxidant polyphenols such as quercetin, catechin and gallic acid have peroxidative activity [44].

High concentrations of flavonoids cause cell toxicity, DNA damage and apoptosis [43]. It was proven that flavonoids can increase reactive oxygen species production through auto-oxidation [45].

However, reactive oxygen species, hydrogen peroxide, superoxide anion and hydroxyl radical are important cell injury mediator, which can react with macro molecules such as lipids, proteins, nucleic acids, carbohydrates and unsaturated fatty acids in cell membranes, and after initial reaction, continued as chain-like reaction which cause cell damage and death [46]. Also, studies have shown that compounds such as quercetin and acacetin can cause cell damage through inhibition of cytochrome P450 activity [2, 14]. Thus, liver damage was observed in the groups treated with henna extract. Because liver plays a major role in metabolic pathway and the regulation of numerous materials, including drugs (activation and detoxification), and excretion of exogenous and endogenous material.

The results of serum protein levels shown a significant increase in the different groups receiving the extract compared to the control group. Studies shown that henna extract lead to increase in total protein concentration of serum [50], which is consistent with current study. Various pathological factors increase or decrease the total protein. The main cause of the increase in total protein is dehydration. In cases such as acute tissue injury, necrosis, surgery, or tumors, total protein increase was seen due to increased protein in acute phase, and chronic antigenic stimulation such as chronic inflammatory diseases and immune-related diseases, due to increased gamma globulin [11]. According to histological studies carried out in present research, which is show liver tissue damage in groups receiving the extract, as well as the presence of darker cytoplasm and high rate basophils in the cytoplasm, which reflects more ribosomal activity in the production of proteins, we can attribute the increase in serum proteins to above mentioned reasons.

Conclusions

It can be concluded that henna extract increases the liver enzymes and liver damage according to the results of enzymatic and histopathological tests conducted in the current study.

Acknowledgments

Hereby, we honored and appreciated all the efforts and afflictions of staff and officials of Islamic Azad University, kazeroon branch, which will provide the research facilities and paved the road to current invaluable results.

REFERENCES

1. Sereshty M, Azari P, Rafiean M, Kheiri S. Use of herbal medicines by pregnant women in Shahre-Kord. *J ReprodInfertil*. 2006 Sep;7(2):125-31
2. Obermeier MT, White RE, Yang CS. Effects of bioflavonoids on hepatic P450 activities. *Xenobiotica*. 1995; 25(6): 575-84.
3. Amin GH. [Alternative Iran medicinal plants]. Tehran:Ministry of Health and Medical Education;1992:1-66. [in Persian].
4. Rechinger KH. *Flora Iranic*. Akademische Druck-u Verlagsanstalt Graz 1968;51:1-2.
5. Fatiha El Babili^{1,3*}, Alex Valentin² and Christian Chatelain. *Lawsonia inermis*: Its Anatomy and its Antimalarial, Antioxidant and Human Breast Cancer Cells MCF7 Activities. *Pharmaceut Anal Acta* 2013, 4:1
6. Nayak B.S., Isitor G., Davis E.M. and Pillai G.K. (2007). The evidence based wound healing activity of *Lawsoniainermis* Linn. *Phytotherapy Research*, **21**: 827-831.
7. Kok AN, Ertekin MV, Avci B. Henna (*Lawsonia inernis* Linn) induced hemolytic anemia in siblings. *Int J ClinPrac* 2004 May;58(5):530-2.
8. Akter A, Neela FA, Khan MS, Islam MS, Alam MF. Screening of Ethanol, Petroleum Ether and Chloroform Extracts of Medicinal Plants, *Lawsoniainermis* L. and *Mimosa pudica* L. for Antibacterial Activity. *Indian J Pharm Sci* 2010 May;72(3):388-92
9. Ali BH, Bashir AK, Tanira MO. Anti-inflammatoy, antipyretic, and analgesic effects of *Lawsoniainermis* L. (henna) in rats. *Pharmacology* 1995 Dec;51(6):356-63
10. Prakash D, Suri S, Upadhyay G, Singh BN. Total phenol, antioxidant and free radical scavenging activities of some medicinal plants. *Int J Food SciNutr*. 2007 Feb;58(1):18-28
11. Kaneko,JJ.,1989,Clinical biochemistry of domestic animal 4thed, new York: Academic press inc, 72: 144-3 89,900-900 1.
12. Mikhaeil BR, Badria FA, Maatooq GT, Amer MM .Antioxidant and immunomodulatory constituents of henna leaves. *Z Naturforsch C*. 2004 Jul-Aug;59(7-8):468-76
13. Sultana N, Choudhary MI, Khan A. Protein glycation inhibitory activities of *Lawsonia inermis* and its active principles. *J Enzyme Inhib Med Chem*. 2009 Feb;24(1):257-61
14. HamedDoostdar, M. Danny Burke, Richard T. Mayer. Bioflavonoids: selective substrates and inhibitors for cytochrome P450 CYP1A and CYP1B1. *Toxicology* 144 (2000) 31–38
15. Al-Rubiay KK, Jaber NN, Al-Mhaawe BH, Alrubaiy LK .Antimicrobial efficacy of henna extracts. *Oman Med J* 2008 Oct;23(4):253-6.
16. Goncalves de Lima Oswaldo Coelho, Jose S de B, Leoneiod Alboguerque Ivan. Antimicrobial compounds from higher plants that of lapachol. *Rev Inst Antibiot* 1971;11(1):21-6.
17. Ali BH, Bashir AK, Tanira MO. Anti-inflammatoy, antipyretic, and analgesic effects of *Lawsoniainermis* L. (henna) in rats. *Pharmacology* 1995 Dec;51(6):356-63
18. Pratt, D.S., Kaplan, M.M. (2000). Evaluation of abnormal liver-enzyme results in asymptomatic patients. *N Engl J Med*, 342(17); 1266-71.
19. Salimuddin; Upadhyaya, K. C.; Baquer, N. Z. (2008). Effects of vanadate on expression of liver araginase in experimen- tal diabetic rats. *IUBMB Life*48(2); 237-40.
20. Giannini, E., Testa, R., Savarino, V. (2005). Liver enzyme alteration: A guild for clinic tons. *CMAJ*, 172; 367-79.
21. Pratt, D.S., Kaplan, M.M. (2000). Evaluation of abnormal liver-enzyme results in asymptomatic patients. *N Engl J Med*, 342(17); 1266-71.
22. Chin, JH.,Abas, HH., Sabariah, I. (2008). Toxicity study of *Orthosiphon stamineus* Benth (MisaiKucing) on Sprague dawley rats. *Trop Biomed*, 25(1); 9-16.
23. Nzegwu C. Toxic effects of the methanolic extract of Law Sonia inermis Roots. *PharmaceutBiol* 1987;25(4):241-245.

24. Perinet I, Lioson E, Tichadou L, Glaizal M, de Haro L. [Hemolytic anemia after voluntary ingestion of henna (*Lawsoniainermis*) decoction by a young girl with G6PD deficiency] [Article in French]. *Med Trop (Mars)*. 2011 Jun;71(3):292-4.
25. SadiyhaYasir AL-Jubory. Lethal Dose (LD50)And Acute Toxicity, Histopathological Effects Of Glycosides Extract of *Lawsonia inermis* (Henna) Leaves In Mice. *Journal of Babylon University/Pure and Applied Sciences/ No.(3)/ Vol.(21):* 2013
26. Montouris G. Gabapentin exposure in human pregnancy: results from the Gabapentin Pregnancy Registry. *Epilepsy Behav* 2003 Jun;4(3):310-7.
27. Handa, S.S., S.P.S. Khanuja, and G. Longo, *DevDuttRakesh-Extraction Technologies for Medicinal and Aromatic Plants. International Centre for Science and High Technology, Italy, 2008.*
28. Aaeinehchi Y. [Iran medicinal plants]. Tehran:Tehran University;1992:1042-3. [in Persian].
29. Hertog MG, Hollman PC, Katan MB. Content of potentially anticarcinogenic flavonoids of 28 vegetables and 9 fruits commonly consumed in the Netherlands. *J Agric Food Chem* 1992 Dec;40(12):2379-83.
30. Trease GE, Evans WC. *Treas and Evans pharmacognosy*. 14th ed. London:Saunders;1996:246-98
31. Zinkham WH, OskiFA. Henna: a potential cause of oxidative hemolysis and neonatal hyperbilirubinemia. *Pediatrics* 1996 May;97(5):707-9.
32. Kim WR, Flamm SL, Di Bisceglie AM, Bodenheimer HC. Serum activity of alanine aminotransferase (ALT) as an indicator of health and disease. *Hepatology*. 2008; 47(4): 1363-70.
33. Romeo S, Sentinelli F, Dash S, Yeo GS, Savage DB, Leonetti F, et al. Morbid obesity exposes the association between PNPLA3 I148M (rs738409) and indices of hepatic injury in individuals of European descent. *Int J Obes (Lond)*. 2010; 34(1): 190-4.
34. Kramer JW, Hoffman WE. Clinical enzymology. In: Kaneko JJ, Harvey JW, Bruss ML. *Clinical biochemistry of domestic animals*. Academic Press. San Diego: Toronto; 1997. 303-25.
35. Ali AT, Penny CB, Paiker JE, Van Niekerk C, Smit A, Ferris WF, et al. Alkaline phosphatase is involved in the control of adipogenesis in the murine preadipocyte cell line, 3T3-L1. *ClinChimActa* . 2005; 354(1-2): 101-9
36. Webber M, Krishnan A, Thomas NG, Cheung BM. Association between serum alkaline phosphatase and C-reactive protein in the United States national health and nutrition examination survey 2005–2006. *ClinChem Lab Med*. 2010; 48(2): 167-73.
37. Abdelgadir, E. H.; Ahmed, R. H.; Adam, S. I. Y.; Husein, A. M. Evaluation of Toxicological Activity (Acute and Sub-Chronic Toxicities) of the Aqueous Extract of *Lawsoniainermis* Seeds on Wistar Rats, *Journal of Pharmacology & Toxicology*;2010, Vol. 5 Issue 7, p324
38. Gohari AR, Hadjiakhoondi A, Sadat-Ebrahimi SE, Saeidnia S, Shafiee A. Cytotoxic terpenoids from *saturejamacrantha* C. A. Mey. *DARU* 2005; 13(4): 177-81. (Persian).
39. Nze-Aguwa C. Toxic effects of the methanolic extract of *lawsonia inermis* roots. *Pharmaceutical Biol*1987;25(4): 241-5.
40. Gradplatto A, Basly JP, Berges R, et al. Canivenc-Lavier pharmacokinetics and metabolism of apigenin in female and male rats after a single oral administration. *Drug Metab Dispos*2005;233(1): 49-54.
41. Wang IK, Lin-Shiau SY, Lin JK. Induction of apoptosis by apigenin and related flavonoids through cytochrome c release and activation of caspase-9 and caspase-3 in leukaemia HL-60 cells. *Eur J Cancer*. 1999; 35(10): 1517-25.
42. Valko M, Leibfritz D, Moncol J, Cronin MT, Mazur M, Telser J. Free radicals and antioxidants in normal physiological functions and human disease. *Int J Biochem Cell Biol*. 2007; 39(1): 44-84.
43. Watjen W, Michels G, Steffan B, Niering P, Chovolou Y, Kampkotter A, et al. Low concentrations of flavonoids is protective in rat H4IIE cells whereas high concentrations cause DNA damage and apoptosis. *J Nutr*. 2005; 135(3): 525-31.
44. Sergedienne E, Jönsson K, Szymusiak H, Tyrakowska B, Rietjens IM, Cenas N. Prooxidant toxicity of polyphenolic antioxidants to HL-60 cells: description of quantitative structure-activity relationships *FEBS Lett*. 1999 Dec; 462(3): 392-6.
45. Gaspar J, Rodrigues A, Laires A, Silva F, Costa S, Monteiro MJ, et al. On the mechanisms of genotoxicity and metabolism of quercetin. *Mutagenesis*. 1994 Sep; 9(5): 445-9.
46. Birdane YO, Buyukokuroglu ME, Birdane FM, Cemek M, Yavuz H. Anti-inflammatory and antinociceptive effects of *Melissa officinalis* L. in rodents. *Rev Med Vet*. 2007; 158(02): 75-81.