J. Appl. Environ. Biol. Sci., 4(12)284-295, 2014
© 2014, TextRoad Publication

ISSN: 2090-4274
Journal of Applied Environmental and Biological Sciences
www.textroad.com

Gross Anatomical and Histological Studies on the Liver of Broiler

Javaid Iqbal, Abdul Latif Bhutto, Muhammad Ghiasuddin Shah, Ghulam Murtaza Lochi, Shaukat Hayat, Niaz Ali, Tariq Khan, Abdul Masood Khan, Shujaat Ali Khan,

Department of Veterinary Anatomy & Histology, Sindh Agriculture University, Tandojam, Sindh, Pakistan

Received: August 27, 2014
Accepted: October 27, 2014

ABSTRACT

The gross anatomical studies shows that mean length of right lobe was 3.64 cm, 5.61 cm and 7.88 cm; length of left lobe was 3.09 cm, 4.93 cm and 7.27 cm; width of right lobe was 1.74 cm, 2.61 cm and 3.67 cm; width of left lobe was 1.38 cm, 2.15 cm and 3.24 cm; thickness of right lobe was 1.30 cm, 1.81 cm and 2.37 cm; thickness of left lobe was 1.14 cm, 1.56 cm and 2.11 cm; circumference of right lobe was 3.40 cm, 5.41 cm and 7.47 cm; and circumference of left lobe was 3.20 cm, 5.16 cm and 7.18 cm. The difference in weight of fresh liver with and without gall bladder, length, width, thickness and circumference of right and left lobe of fresh liver of broiler from 2nd to 6th week was significant ($P<0.05$).

Histological study showed that mean diameter of hepatocytes of liver of broiler from 2nd, 4th and 6th week of age was 24.33 µm, 34.93 µm and 46.20 µm which was significant ($P<0.05$). The mean diameter of central vein of fresh liver of broiler from 2nd 4$^{th\ and}$ 6th week of age was 715.53 µm, 718.87 µm and 723.13 µm which was non-significant ($P>0.05$).

Anatomical study showed that mean weight of gall bladder of broiler from 2nd, 4th and 6th week was 0.50 gm, 0.95 gm and 1.28 gm; length of gall bladder from dorsal to ventral side was 0.98 cm, 1.76 cm and 2.62 cm; width of gall bladder from lateral sides was 0.70 cm, 1.03 cm and 1.51 cm; thickness of gall bladder was 0.60 cm, 1.04 cm and 1.42 cm; circumference of gall bladder was 1.51 cm, 2.30 cm and 3.12 cm. The difference in weight, length, width, thickness and circumference of gall bladder of broiler from 2nd to 6th week was significant ($P<0.05$).

Histological study showed that the thickness of tunica mucosa of gall bladder of broiler from 2nd, 4th and 6th week was 749.3 µm, 856.0 µm and 976.93 µm; mean thickness of tunica muscularis was 668.67 µm, 768.1 µm and 876.67 µm; and mean thickness of tunicamucosa was 601.0 µm, 684.67 µm and 781.67 µm. The difference in thickness of tunica mucosa, muscularis and serosa of gall bladder of broiler from 2nd to 6th week was significant ($P<0.05$).

The mean weight of fresh liver with and without gall bladder, length, width, thickness and circumference of right and left lobe of fresh liver of broiler was increased in 6th week of broiler as compared to 2nd week of broiler. The mean diameter of hepatocytes and central vein of fresh liver and of broiler were also increased in 6th week of broiler as compared to 2nd week of broiler. Similarly, weight, length, width, thickness and circumference of gall bladder of broiler were significantly increased in 6th week of broiler as compared to 2nd week of broiler. On the basis of above findings it can be concluded that age significantly affected the gross anatomical and micrometrical aspects of the liver and gall bladder of broiler.

KEYWORDS: Gross Anatomical, Histological Studies, Liver, Broiler, Tandojam

INTRODUCTION

The poultry industry has occupied a leading role among agricultural industries in many parts of the world. Chicken meat production has been increase in all continents with the highest in Asia and South America. The Asia is leading the world in poultry meat production, followed by North and Central America which had the lead until 1990. In 2005 Asia and South America contributed 50% to global poultry meat production (Daghir, 2008). Poultry meat is the second most widely eaten meat in the world, accounting for about 30% of meat production worldwide (Raloff, 2003).

The liver is the largest internal organ, firm and has prominent sharply defined edges (Clark, 2005). Liver is the largest gland and one of the most important organs which acts as a clearing house for substances that enter the body (Sarkarati and Doustar, 2012). The liver is a large digestive organ and its development is very interesting the liver develops from the hepatic diverticulum, an out-pocket of ventral gut epithelium the hepatic diverticulum gives rise to the liver, the gall bladder and bile ducts (Medlock and Haar, 1983). The vasculogenesis of the developing liver occurs through differentiation of the portal vein, the hepatic artery, and the sinusoids (DeRuiter *et al.*, 1993).

Anatomically bird liver is divided into right and left lobes which are joined cranially at the midline. The right lobe is larger in the domestic fowl and the left lobe is subdivided into the dorsal and ventral parts (Whitlow, 2000; Caceci, 2006). The lobes of liver are with specific shapes and sizes. The size of the chicken

***Corresponding Author:** Javaid Iqbal, Department of Veterinary Anatomy & Histology, Sindh Agriculture University, Tandojam, Sindh, Pakistan

liver is tightly controlled during development through adulthood (Monga*et al*., 2001). The left and right lobes join at the midline. In most avian species the left lobe is slightly smaller (King and McLelland, 1984 and Gould, 1992). The size of the lobes varies greatly; as does their relative size each lobe is drained by separate bile ducts into the distal ascending loop of duodenum (King and McLelland, 1984; Gould, 1992). The liver parenchyma of birds resemlbe the liver of mammalian but there is some different in histological features such as absent of lobules and interlobular trabeculae, its fact that principal cell of liver is the hepatocyte (Dyce *et al*., 2002; King, 1984). The avian liver changes in color and consistency during the phases of life (Reddy, 2000). The color of the liver varies with diet. Baby chicks and poults (a young fowl) tend to have a liver that is yellow in color due to yolk absorption. The adult bird usually has a dark red to red brown colored liver (Clark, 2005). Liver secretes bile and metabolizes proteins, carbohydrates, and fats; stores glycogen, vitamins, and other substances; synthesizes coagulation factors; removes wastes and toxic substances from the blood; regulates blood volume; and destroys old red blood cells (Sarkarati and Doustar, 2012). As in other vertebrates, the avian liver provides exocrine secretions to the digestive tract and its exocrine secretion is called bile, which emulsify fats and raise the pH of the duodenal digest (Hoppe, 1999).

Liver tissue consists of a mass of cells tunneled with bile ducts and blood vessels (Altan*et al*., 2000). The hepatocytes are arranged in plate of two cell layers thick around the bile canaliculi (Turk, 1982). Bile is synthesized in the hepatocytes and secreted into bile canaliculi located on the lateral surfaces of adjoining liver cells. These canaliculi drain into interlobular ducts, which unite to form the right and left hepatic ducts, which in turn drain into the gall bladder (Hoppe, 1999).

Most vertebrates have gall bladder (cholecyst orbiliary vesicle), which is a small organ that aids mainly in fat digestion and concentrates bile produced by the liver(Hogan, 2008). Several species of birds also lack a gall bladder for example lampreys (Romer and Parsons, 1977). Unlike mammals, the bird delivers bile to the duodenum via 2 ducts that join the duodenum in the mid-to distal portion of the loop (Borges *et al*., 1999). The gall bladder is found on the visceral surface of the right lobe of liver of chickens, ducks and geese (King and McLelland, 1984). The avian gall bladder is attached to the liver lobe and can be easily examined by moving the liver to one side. This sac like structure is greenish-black in color due to presence of bile (Clark, 2005).

Histologicaly avian gall bladder is composed of tunica mucosa, tunica muscularis and tunica serosa. Epithelium of tunica mucosa is lined by non-ciliated simple columner cell and consisted of a layer of connective tissue with elastic and muscle fibres. Tunica muscularis consisted smooth muscle fibers and abundant intervening connective tissue, tunica serosa consist of coarse collagen fibre and elastic fibres. All epithelial cells are basally situated and containing oval nucleas.on the luminal surface of whole gall bladder simple isometric folds are distributed regularly (Behzad, 2013; Maya *et al*., 2012; Mobini, 2012).

Normal gross anatomy and histology of liver and gall bladder of broilers (raised locally) is necessary in diagnosis of various diseases, as such information is scanty in academic record. Therefore, the present research has been designed to understand normal gross anatomy and histology of liver and gall bladder of 2nd, 4th and 6th week's age broilers.

MATERIAL AND METHODS

The study was performed on 45 healthy broilers of 2nd, 4th and 6th weeks of age purchased from local market and poultry farms of Tandojam. The birds were divided into three groups i.e. A (2nd weeks age), B (4th week age) and C (6th week age) each having 15 birds. Each bird samples of liver and gall bladder were collected and packed in polythene bags and were brought in the Department of Anatomy and Histology laboratory for the process of gross anatomical and histological studies.

Gross anatomical evaluation

Various measurements including weight, length, width, thickness and circumference of liver and gall bladder were recorded using measuring tape, vernier caliper and electric balance.

Microscopic anatomical/histological method

Approximately 1 cm^3 pieces of the liver and gall bladder of broiler were cut in a particular orientation and processed for histological techniques as follows:

Fixation:-

The tissue specimens were washed with normal saline (the solution is 9 grams (gm) of sodium chloride (NaCl) dissolved in 1 liter of water) and then transferred to 10% neutral buffered formalin (4% formaldehyde in phosphate buffered saline) for 1 hour.

Washing:-

Washing was carried out under running tape water for 6-8 hrs to remove fixative.

Dehydration:-

- A graded series of mixtures (30%, 50%, 70%, 80%, 95% for 2 hrs and in 100% ethanol for ½ twice hr)

of water and ethanol was used.

Clearing:-

The clearing of samples was performed in 100% ethanol replaced by solvent miscible with the embedding medium. When using paraffin the solvent was usually xylene.

Infiltration:-

The pieces of organs were placed in 50:50 mixtures of xylene for (30 mins) and paraffin then transferred to 100% paraffin and placed in oven at 60°C for 1 hr.

Embedding:-

The tissue section were oriented and embedded in a paraffin block. The block was placed in ice water to solidify.

Sectioning:-

After embedding of the tissue section in paraffin and the blocks were trimmed to a trapezoid shape and then placed in the chuck of a rotatory microtome which was used as sectioning instrument that allowed for the cutting of extremely thin slices of the material, known as sections (5-7 µm) as knife moved the block of the piece of organ up and down.

Mounting:-

- The paraffin ribbons were transferred directly to microscope slides that had coated with egg albumen with the aid of a small brush the albumen acted as an adhesive and stuck the sections to the slide.
- The slides were placed on a warming tray and distilled water was added to float the paraffin sections and then allowed to expand and straighten out.
- The slides were allowed to dry in incubator at 60°C for 30 mins.
- Staining:-

Hematoxylin and eosin (H&E) is the most commonly used combination of staining method for routine histology. Hematoxylin, a basic dye, stained nuclei blue due to affinity to nucleic acids and eosin an acidic dye stained the cytoplasm pink. The procedure applied in the present study was as follows:

- Slides with paraffin sections on them must have the paraffin removed for staining
- The slides were placed in xylene for 10 mins
- Next a second change of xylene for 10 mins
- Slides were then rehydrated through a grade series of alcohols to distilled water
- The slides were then placed in hematoxylin for 3 to 5 mins
- The slides were then placed in 70% ethanol for 2 to 5 mins
- Counter stained with eosin in 70% ethanol for 2 to 5 mins
- Rinsed off excess eosin
- Dehydrated and cleared in xylene
- A small drop of Canada Balsum was added in to the slide and finally a cover slip
- The slides were allowed to dry before examining.

The stained slides were interpreted on light microscope (Cxl Digital Digi1- 1500 Labomed, Labo American Inc. USA). The photography of capsule, hepatic labule, hepatocytes, sinosoids, portal traid, portal vein, hepatic artery, bile duct and central vein of liver. The tunica mucosa, tunica muscularis and tunica serosa of gall bladder were performed.

Morphometric analysis

The data for age related gross observations and histological sections of liver and gall bladder of broilers in each group were recorded for following parameters.

- Gross anatomy of liver and gall bladder.
- Histology of liver and gall bladder.

Statistical analysis

The means (X) and standard deviation (SD) for each gross and microscopic anatomical parameter of broilers were computed using Microsoft Excel Software. Group means of length, width, thickness, circumference, weight of liver and gall bladder of broilers birds were compared using statistical computer software M Stat-C (Gomez and Gomez, 2000).

RESULTS

The gross anatomical and histological studies on the liver and gall bladder of 45 broilers (Cobb) were performed. The biometrical measurements, randomly selected photography for gross anatomical and histological structures of the various regions of liver and gall bladder of 2nd, 4th and 6th week age of broiler was investigated.

1) Biometry of liver with gall bladder of broiler

1.2) Weight of fresh liver.

The biometrical studies also included the weight of fresh liver without gall bladder of broiler from 2nd, 4th and 6th week of age is presented in Table No.2. Electric balance used for weight of the organs. The minimum and maximum weight of fresh liver without gall bladder of broiler from 2nd, 4th and 6th week of age was 6.70-21.0, 25.50-34.40 and 40.5-59.50 gm respectively (Fig.1). The mean and standard deviation of weight of fresh liver without gall bladder of broiler from 2nd, 4th and 6th week of age was 15.27±4.57, 29.8±2.75 and 47.980±5.93 gm respectively. The F-value of weight fresh liver without gall bladder in between 2nd, 4th and 6th week of broiler was 190 and considered highly significant (P<0.01).

Table No.2 Weight of liver without gallbladder of broiler.

Age in week	Minimum & Maximum (gm)	Mean ± Standard Deviation
2nd	6.70-21.0	15.27±4.57
4th	25.50-34.40	29.8±2.75
6th	40.0-59.50	47.980±5.93

F-Value 190

Remarks (P<0.01) Highly Significant

Fig.1 Weight of liver of broiler.

1.3) Length of right lobe from cranial to caudal border of liver of broiler.

The biometrical studies include the length of right lobe of liver of broiler from 2nd, 4th and 6th week of age is presented in Table No.3. The minimum and maximum length of right lobe of fresh liver of broiler from 2nd to 6th week of age was 2.90-4.30, 4.50-6.20 and 7.0-8.50 cm respectively (Fig.2). The mean and standard deviation of length of fresh liver of broiler from 2nd, 4th and 6th week of age was 3.640±0.44, 5.607±0.54 and7.887±0.55cm respectively. The F-value of length of right lobe of fresh liver in between 2nd, 4th and 6th week of broiler was 254 and considered highly significant (P<0.01).

Table No.3 Length of right lobe from cranial to caudal border of liver of broiler.

Age in week	Minimum & Maximum (cm)	Mean ± Standard Deviation
2nd	2.90-4.30	3.640±0.44
4th	4.50-6.20	5.607±0.54
6th	7.00-8.50	7.887±0.55

F-Value 254

Remarks (P<0.01) Highly Significant

1.4) Length of left lobe from cranial to caudal border of liver of broiler.

The biometrical studies includes the length of left lobe of liver of broiler from 2nd, 4th and 6th of age is presented in Table No.4. The minimum and maximum length of left lobe of fresh liver of broiler from 2nd, 4th and 6th week of age was 2.30-3.80, 2.00-5.70 and 6.70-8.0 cm respectively. The mean and standard deviation of length of left lobe fresh liver of broiler from 2nd, 4th and 6th week of age was 3.09±0.37, 4.93±0.55 and 7.27±0.47 cm respectively. The F-value of length of left lobe of fresh liver in between 2nd, 4th and 6th week of broiler was 293 and considered highly significant (P<0.01).

Table No.4 Length of left lobe from cranial to caudal border of liver of broiler.

Age in week	Minimum & Maximum (cm)	Mean ± Standard Deviation
2nd	2.30-3.80	3.09±0.37
4th	2.00-5.70	4.93±0.55
6th	6.70-8.00	7.27±0.47

F-Value 293

Remarks (P<0.01) Highly Significant

1.5) Width of right lobe from lateral to medial border of liver of broiler.

The biometrical studies include the width of right lobe of liver of broiler from 2nd, 4th and 6th week of age is presented in Table No.5. The minimum and maximum of width right lobe of liver of broiler from 2nd, 4th and 6th week of age was1.30-2.20, 2.20-3.0 and 3.0-5.0 cm respectively. The mean and standard deviation of width of fresh liver of broiler from 2nd, 4th and 6th week of age was 1.747±0.27, 2.607±0.23 and 3.6733±0.51cm respectively. The F-value of width of right lobe of fresh liver in between 2nd, 4th and 6th week of broiler was 105 and considered highly significant (P<0.01).

Table No.5 Width of right lobe from lateral to medial border of liver of broiler.

Age in week	Minimum & Maximum (cm)	Mean ± Standard Deviation
2nd	1.30-2.20	1.747±0.27
4th	2.20-3.0	2.607±0.23
6th	3.0-5.0	3.6733±0.51

F-Value 105
Remarks (P<0.01) Highly Significant

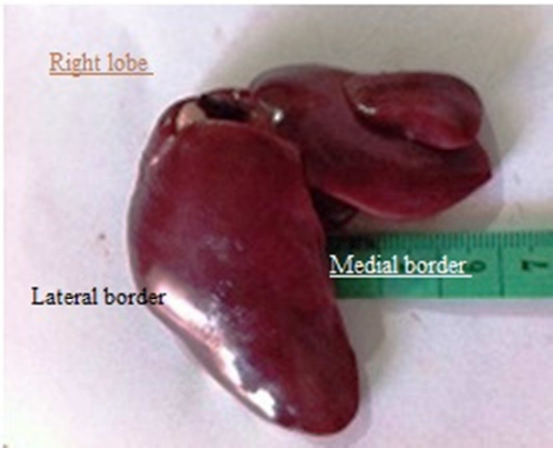

Fig.4: Width of right lobe from lateral to medial border of liver of broiler

1.6) Width of left lobe of liver of broiler.

The biometrical studies includes the width of left lobe of liver of broiler from 2nd, 4th and 6th week of age is presented in Table No.6. Measuring tape or inch tape used for width of the organs. The minimum and maximum width of left lobe of fresh liver of broiler from 2nd, 4th and 6th week of age was 1.0-1.70, 1.80-2.60 and 2.70-4.70 cm respectively. The mean and standard deviation of width of left lobe fresh liver of broiler from 2nd, 4th and 6th week of age was 1.387±0.24, 2.1533±0.22 and3.240±0.50 cm respectively. The F-value of width of left lobe of fresh liver in between 2nd, 4th and 6th week of broiler was 110 and considered highly significant (P<0.01).

Table No.6 Width of left lobe from lateral to medial border of liver of broiler.

Age in week	Minimum & Maximum (cm)	Mean ± Standard Deviation
2nd	1.0-1.70	1.387±0.24
4th	1.80-2.60	2.1533±0.22
6th	2.70-4.70	3.240±0.50

F-Value 110
Remarks (P<0.01) Highly Significant

1.7) Thickness of right lobe from parietal to visceral surface of liver of broiler.

The biometrical studies includes the thickness of right lobe of liver of broiler from 2nd, 4th and 6th week of age is presented in Table No.7. The minimum and maximum thickness of right lobe of fresh liver of broiler from 2nd, 4th and 6th week of age was1.0-1.60, 1.50-2.40 and 2.0-2.80 cm respectively. The mean and standard deviation of thickness of right lobe fresh liver of broiler from 2nd, 4th and 6th week of age was 1.30±0.15, 1.8133±0.23 and 2.3733±0.24 cm respectively. The F-value of thickness of right lobe of fresh liver in between 2nd, 4th and 6th week of broiler was 97.3 and considered highly significant (P<0.01).

Table No.7 Thickness of right lobe from parietal to visceral surface of liver of broiler.

Age in week	Minimum & Maximum (cm)	Mean ± Standard Deviation
2nd	1.0-1.60	1.30±0.15
4th	1.50-2.40	1.8133±0.23
6th	2.0-2.80	2.3733±0.24

F-Value 97.3
Remarks (P<0.01) Highly Significant

1.8) Thickness of left lobe from parietal to visceral surface of liver of broiler.

The biometrical studies includes the thickness of left lobe of liver of broiler from 2nd, 4th and 6th week of age is presented in Table No.8. The minimum and maximum thickness of left lobe of fresh liver of broiler from 2nd, 4th and 6th week of age was 0.80-1.40, 1.30-1.80 and 1.80-2.50 cm respectively. The mean and standard deviation of thickness of left lobe fresh liver of broiler from 2nd, 4th and 6th week of age was 1.147±0.15, 1.567±0.16 and 2.113±0.19 cm respectively. The F-value of thickness of left lobe of liver in between 2nd, 4th and 6th week of broiler was 121 and considered highly significant (P<0.01).

Table No.8 Thickness of left lobe from parietal to visceral surface of liver of broiler.

Age in week	Minimum & Maximum (cm)	Mean ± Standard Deviation
2nd	0.80-1.40	1.147±0.15
4th	1.30-1.80	1.567±0.16
6th	1.80-2.50	2.1133±0.19

F-Value 121
Remarks (P<0.01) Highly Significant

Histology of broiler liver of 2nd, 4th and 6thweeks of age.

Histologically the liver of broiler was composed of capsule, hepatocytes, sinusoids, hepatic lobule, portal triad and biliary system. This includes portal vein, hepatic artery, bile duct and lymphatic vessel. The micrometry of central vain and hepatocyes were performed under light microscope.

1.11) Diameter of hepatocytes of fresh liver of broiler.

The histological studies includes the diameter of hepatocytes of fresh liver of broiler from 2nd, 4th and 6th week of age is presented in Table No.11. The minimum and maximum diameter of hepatocytes of fresh liver of broiler from 2nd, 4th and 6th week of age was 17.30-30.0, 31.0-39.0 and 40.0-52.0 µm respectively. The mean and standard deviation of diameter of hepatocytes of fresh liver of broiler from 2nd, 4th and 6th week of age was 24.33±4.89, 34.93±2.71and 46.20±3.20 µm respectively. The F-value of diameter of hepatocytes of fresh liver in between 2nd, 4th and 6th week of broiler was 127 and considered highly significant (P<0.01).

Table No.11 Diameter of hepatocytes of fresh liver broiler.

Age in week	Minimum & Maximum (µm)	Mean ± Standard Deviation
2nd	17.0-30.0	24.33±4.89
4th	31.0-39.0	34.93±2.71
6th	40.0-52.0	46.20±3.20

F-Value 127
Remarks (P<0.01) Highly Significant

1.12) Diameter of central vein of fresh liver of broiler.

The histological studies includes the diameter of central vein of fresh liver of broiler from 2nd, 4th and 6th week of age is presented in Table No.12. The minimum and maximum diameter of central vein of fresh liver of broiler from 2nd, 4th and 6th week of age was 690.0-780.00, 700.0-785.0 and 700.0-790.00 µm respectively. The mean and standard deviation of diameter of central vein of fresh liver of broiler from 2nd, 4th and 6th week of age was 715.53±22.88, 718.87±23.48 and 723.13±23.19 µm respectively. The F-value of diameter of central vein of fresh liver in between 2nd, 4th and 6th week of broiler was 0.40 and considered non significant (P>0.5).

Table No.12 Diameter of central vein of liver of broiler.

Age in week	Minimum & Maximum (µm)	Mean ± Standard Deviation
2nd	690.0-780.0	715.53±22.88
4th	700.0-785.0	718.87±23.48
6th	700.0-790.0	723.13±23.19

F-Value 0.40
Remarks (P>0.5) Non-significant

1.13) Weight of gall bladder of broiler.

The biometrical studies includes the weight of gall bladder of broiler from 2nd, 4th and 6th week of age is presented in Table No.12. The minimum and maximum weight of gall bladder of broiler from 2nd, 4th and 6th week of age was 0.40-0.70, 0.70 -1.20 and 1.10-1.40 gm respectively. The mean and standard deviation of weight of gall bladder of broiler from 2nd, 4th and 6th week of age was 0.50±0.96, 0.95±0.14 and 1.28±0.09 gm respectively. The F-value of weight of gall bladder in between 2nd, 4th and 6th week of broiler was 186 and considered highly significant (P<0.01).

Table No.13 Weight of gall bladder of broiler.

Age in week	Minimum & Maximum (gm)	Mean ± Standard Deviation
2nd	0.40-0.70	0.5067 ±0.96
4th	0.70 -1.20	0.9467±0.14
6th	1.10-1.40	1.2800±0.09

F-Value 186
Remarks (P<0.01) Highly Significant

1.14) Length from dorsal to ventral side of gall bladder of broiler.

The biometrical studies includes the length of gall bladder from dorsal to ventral side of broiler from 2nd, 4th and 6th week of age is presented in Table No.14. The minimum and maximum length of gall bladder from dorsal to ventral side of broiler from 2nd, 4th and 6th week of age was 0.80-1.20, 1.60-1.90 and 2.40-2.80 cm respectively. The mean and standard deviation of length of gall bladder from dorsal to ventral side of broiler from 2nd, 4th and 6th week of age was 0.98±0.11, 1.76±0.12 and 2.62±0.14 cm respectively. The F-value of length of gall bladder from dorsal to ventral side in between 2nd, 4th and 6th week of broiler was 640 and considered highly significant (P<0.01).

Table No.14 Length from dorsal to ventral side of gall bladder of broiler.

Age in week	Minimum & Maximum (cm)	Mean ± Standard Deviation
2nd	0.80-1.20	0.9867±0.11
4th	1.60-1.90	1.7600±0.12
6th	2.40-2.80	2.6200±0.14

F-Value 640
Remarks (P<0.01) Highly Significant

1.15) Width from lateral sides of gall bladder of broiler.

The biometrical studies includes the width of gall bladder from lateral sides of broiler from 2nd, 4th and 6th week of age is presented in Table No.15. The minimum and maximum width of gall bladder from lateral sides of broiler from 2nd, 4th and 6th week of age was 0.60-0.80, 0.80-1.20 and 1.40-1.70 cm respectively. The mean and standard deviation of width of gall bladder from lateral sides of broiler from 2nd, 4th and 6th week of age was 0.70±0.08, 1.03±0.12 and 1.51±0.09 cm respectively. The F-value of width of gall bladder from lateral sides in between 2nd, 4th and 6th week of broiler was 247 and considered highly significant (P<0.01).

Table No.15 Width from lateral sides of gall bladder of broiler.

Age in week	Minimum & Maximum (cm)	Mean ± Standard Deviation
2nd	0.60-0.80	0.7067±0.08
4th	0.80-1.20	1.0333±0.12
6th	1.40-1.70	1.5133±0.09

F-Value 247
Remarks (P<0.01) Highly Significant

1.16) Thickness of the gall bladder of broiler.

The biometrical studies includes the thickness of gall bladder of broiler from 2nd, 4th and 6th week of age is presented in Table No.16. The minimum and maximum thickness of gall bladder from upper to lower sides of broiler from 2nd, 4th and 6th week of age was 0.50-0.70, 0.80-1.20 and 1.20-1.60 cm respectively. The mean and standard deviation of thickness of gall bladder from upper to lower sides of broiler from 2nd, 4th and 6th week of age was 0.60±0.08, 1.04 ±0.140 and 1.42±0.14 cm respectively. The F-value of thickness of gall bladder from upper to lower sides in between 2nd, 4th and 6th week of broiler was 162 and considered highly significant (P<0.01).

Table No.16 Thickness of the gall bladder of broiler.

Age in week	Minimum & Maximum (cm)	Mean ± Standard Deviation
2nd	0.50-0.70	0.60±0.08
4th	0.80-1.20	1.04 ±0.14
6th	1.20-1.60	1.4267 ±0.14

F-Value 162
Remarks (P<0.01) Highly Significant

1.17) Circumference of the gall bladder of broiler

The biometrical studies includes the circumference of gall bladder of broiler from 2nd, 4th and 6th week of age is presented in Table No.17. The minimum and maximum circumference from middle of entire gall bladder of broiler from 2nd, 4th and 6th week of age was 1.30-1.70, 2.0-2.50 and 3.00-3.30 cm respectively. The mean and standard deviation of circumference from middle of entire gall bladder of broiler from 2nd, 4th and 6th week of age was 1.51±0.15, 2.30±0.18 and 3.12±0.19 cm respectively. The F-value of circumference from middle of

entire gall bladder in between 2nd, 4th and 6th week of broiler was 424 and considered highly significant (P<0.01).

Table No.17 Circumference of the gall bladder of broiler.

Age in week	Minimum & Maximum (cm)	Mean ± Standard Deviation
2nd	1.30-1.70	1.5133 ±0.15
4th	2.0-2.50	2.3000±0.18
6th	3.0-3.30	3.1267 ±0.19

F-Value 424
Remarks (P<0.01) Highly Significant

Histology of gall bladder of broiler of 2nd, 4th and 6th weeks of age.

The gall bladder was composed of tunica mucosa, tunica muscularis and tunica serosa. Epithelium of tunica mucosa was lined by non-ciliated simple columner cell and consisted of a layer of connective tissue with elastic and muscle fibers. Tunica muscularis consisted smooth muscle fibers and abundant intervening connective tissue, tunica serosa consist of coarse collagen fibre and elastic fibres. All epithelial cells were basally situated and containing oval nucleus and on the luminal surface of whole gall bladder simple isometric folds were distributed regularly.

1.18) Thickness of tunica mucosa of gall bladder of broiler.

The histological studies includes the length of tunica mucosa of gall bladder of broiler from 2nd, 4th and 6th week of age is presented in Table No.18. The minimum and maximum length of tunica mucosa of gall bladder of broiler from 2nd, 4th and 6th week of age was 710-780, 570-910 and 950-995 µm respectively. The mean and standard deviation of length of tunica mucosa of gall bladder of broiler from 2nd, 4th and 6th week of age was 749.3±23.44, 856±81.44 and 977±13.68 µm respectively. The F-value of length of tunica mucosa of gall bladder in between 2nd, 4th and 6th week of broiler was 79.2 and considered highly significant (P<0.01).

Table No.18 Thickness of tunica mucosa of gall bladder of broiler.

Age in week	Minimum & Maximum (µm)	Mean ± Standard Deviation
2nd	710-780	749.3±23.44
4th	570-910	856±81.44
6th	950-995	977±13.68

F-Value 79.2
Remarks (P<0.01) Highly Significant

1.19) Thickness of tunica muscularis of broiler.

The histological studies included the length of tunica muscularis of gall bladder of broiler from 2nd, 4th and 6th week of age is presented in Table No.19. The minimum and maximum length of tunica muscularis of gall bladder of broiler from 2nd, 4th and 6th week of age was 630-695, 740-790 and 830-895 µm respectively. The mean and standard deviation of length of tunica muscularis of gall bladder of broiler from 2nd, 4th and 6th week of age was 669±22.07, 768±18.0 and 876.67±17.29 µm respectively. The F-value of length of tunica muscularis of gall bladder in between 2nd, 4th and 6th week of broiler was 439 and considered highly significant (P<0.01).

Table No.19 Thickness of tunica muscularis of gall bladder of broiler.

Age in week	Minimum & Maximum (µm)	Mean ± Standard Deviation
2nd	630-695	669± 22.07
4th	740-790	768±18.0
6th	830-895	876.67±17.3

F-Value 439
Remarks (P<0.01) Highly Significant

1.20) Thickness of tunica serosa of gall bladder of broiler.

The histological studies includes the length of tunica serosa of gall bladder of broiler from 2nd, 4th and 6th week of age is presented in Table No.20. The minimum and maximum length of tunica serosa of gall bladder of broiler from 2nd, 4th and 6th week of age was 575-620, 670-695 and 750-795 µm respectively. The mean and standard deviation of length of tunica serosa of gall bladder of broiler from 2nd, 4th and 6th week of age was 601±14.29, 684.7±7.1 and 782±12.05 µm respectively. The F-value of length of tunica muscularis of gall bladder in between 2nd, 4th and 6th week of broiler was 917 and considered highly significant (P<0.01).

Table No.20 Thickness of tunica serosa of gall bladder of broiler.

Age in week	Minimum & Maximum (µm)	Mean ± Standard Deviation
2nd	575-620	601±14.29
4th	670-695	684.67±7.1
6th	750-795	782±12.0

F-Value 917
Remarks (P<0.01) Highly Significant

DISCUSSIONS

The present research was carried out to study age related gross anatomical and histological changes in liver and gall bladder of 2nd, 4th and 6th week of broiler (Cobb).

The mean weight of liver without gall bladder of broiler from 6th week of age was 47.98 gm. These findings are slightly lower than Ishi *et al.,* (2000) who observed that liver of broiler was weighing between 45 to 60 gm. The present study shows weight at 2nd and 4th week of age as 15.27 and 29.8 gm and is in near with Latimer, (1925) who reported that the weight of chicken liver increases 33.9 gm between hatching and maturity. Purton, (1969) reported that the avian liver weighing from 7.50 to 25.00 gm. Riddell, (1997) described that liver of newly hatched chick weighing about 5.00 to 8.00 gm and increased significantly according to the growth of chicks. Turk, (1982) reported that avian liver having weight of 9.50 to 35.00 gm. However, Longo *et al.,* (2003) obtained differences in weight of liver of newly hatched chicken. The results reported by following authors were also in close range of the present study. Hanan, (2013) has reported that the liver of coot bird (*Fulicaatra*) having an average weight of 35.00 to 45.00 gm. Zebisch *et al.,* (2004) report that the liver of pigeons weighing about 8 to 10 gm and the liver of quail even less. In present study the weight at age of 2nd, 4th and 6thweeks was highly significant (P<0.01) while Sunday *et al.,* (2012) also reported statistical significant differences (P<0.05) in the liver of the quail and pigeon.

The study the mean length of right lobe of liver of broiler from 2nd, 4th and 6thweek of age was 3.64 cm, 5.61 cm and 7.89 cm, respectively. These findings are nearly in agreement with Lucas and Denington, (1956) observed the length of right lobes varies from 2.50 to 8.00 cm. Ishi *et al.,* (2000) reported that liver of broiler having length of right lobes varies from 2.00 to 7.00 cm.

In present study the mean length left lobe of liver of broiler from 2nd, 4th and 6th week of age was 3.09 cm, 4.93 cm and 7.27 cm, respectively. The present findings are in nearly agreement with Lucas and Denington, (1956) reported that length of left lobes varies from 2.40 to 7.50 cm. Ishi *et al.,* (2000) stated that length of left lobes of liver of broiler ranged from1.50 to 6.00 cm.

The present study the mean width of right lobe of liver of broiler from 2nd, 4th and 6th week of age was 1.75 cm, 2.61 cm and 3.67 cm, respectively. The similar findings are supported by Lucas and Denington, (1956) observed the width of right lobes ranged from 1.10 to 4.50 cm. Ishi *et al.,* (2000) delineated that liver of broiler having width of right lobes varies from 2.20 to 4.00 cm.

The mean width of left lobe of liver of broiler from 2nd, 4th and 6th week of age was 1.39 cm, 2.15 cm and 3.24 cm, respectively. The findings reported by following authors are nearly in agreement with present study. Lucas and Denington, (1956) reported that width of left lobes varies from 1.50 to 3.50 cm. Ishi *et al.,* (2000) observed that width of left lobes of liver varies from 1.50 to 3.30 cm.

The mean thickness of right lobe liver of broiler from 2nd, 4th and 6th week of age was 1.30 cm, 1.81 cm and 2.37 cm, respectively. Findings of the present study is lower with Lucas and Denington, (1956) reported thickness of right lobes of liver ranging from 1.50 to 3.00 cm. Ishi *et al.,* (2000) observed that liver of broiler having thickness of right lobes ranged from 1.50 to 2.50 cm. Maria, (2006) stated that thickness of a right lobe of liver having size of 2.50 to 5.00 cm.

In present study the mean thickness of left lobe liver of broiler from 2nd, 4th and 6th week of age was 1.15 cm, 1.57 cm and 2.11 cm, respectively. Present study is in nearly agreement with Lucas and Denington, (1956) who delineated that thickness of left lobes of liver having size from 0.90 to 2.00 cm. Ishi *et al.,* (2000) who reported that thickness of left lobes of liver varies from 1.00 to 4.00 cm. Maria, (2006) promulgated that thickness of left lobe of liver having size of 2.75 to 5.50 cm.

In present study the mean circumference of right lobe liver of broiler from 2nd, 4th and 6th week of age was 3.40 cm, 5.41 cm and 7.47 cm, respectively. Present findings are higher than reported by Lucas and Denington, (1956) reported circumference of right lobes of avian liver varies between 1.50 to 2.50 cm. Ishi *et al.,* (2000) observed that liver of broiler having circumference of right lobes varies between 3.50 to 6.00 cm.

In the present study the mean circumference of left lobe liver of broiler from 2nd, 4th and 6th week of age was 3.20 cm, 5.16 cm and 7.187 cm, respectively. Present findings are higher to reported by Lucas and Denington, (1956) regarding circumference of left lobes of avian liver ranged between 2.50 to 6.50 cm. Ishi *et al.,* (2000) reported that circumference of left lobes of liver varies between 2.00 to 2.50 cm. The differences in weight, length, width, thickness and circumference of right and left lobe of liver of broiler reported by above authors were due to differences in age, breeds, quality of feeds, environment and farming techniques.

In present study the mean diameter of hepatocytes of liver of broiler of 6th week of age was 46.20 µm. The results of present study was similar to hepatocyes of female and lower then hepatocytes of male confirmed by Peter *et al.,* (2012) reported that the hepatocyte diameter of males was higher (50.51 µm) than the hepatocyte diameter of females (46.79 µm).

In present study diameter of hepatocytes of liver from 2nd, 4th and 6th week of age was highly significant (P<0.01). Whereas Peter *et al.,* (2012) reported that the hepatocyte diameter of males and females was significant (P<0.01). Ishi *et al.,* (2001) reported that the average diameter of hepatocytes showed significant

difference between different age groups. However differences in hepatocytes reported by previous authors are due to difference in age and quality of feeds.

In present study the mean diameter of central vein of liver of broiler from 2nd, 4th and 6th week of age was non significant. The similar findings are reported by Ishi *et al.,* (2001) that the average diameter of central vein of liver of broiler showed non significant difference between different age groups.

In present study the mean weight of gall bladder of broiler of 2nd and 6th week of age was 0.50 gm and 1.28 gm, respectively. These findings are in agreement with Yamada and Hoshino, (1972) found some variations in the weight of gall bladder of avian ranging from 0.50 to 1.50 gm. Maya *et al.,* (2012) reported that gall bladder weight increased from 0.03 gm by day-old to 1.26 gm by 22 weeks almost similar. Mobini, (2012) described that the weight of gall bladder was in the range of 1.00 to 2.50 gm higher in values then from presemt study.

In present study the mean length of gall bladder from dorsal to ventral side of broiler of 6th week of age was 2.62 cm. In the present study values are in the range of results reported by Haffajee, (2000) that the mean length of the gall bladder ranged from 2.21 cm to 3.60 cm. Braun and Kruger, (2013)stated that length of gall bladder varied from 1.50 cm to 2.6 cm. Mobini, (2012) adumbrated that length of gall bladder was in close range between 2.00 to 3.00 cm.

In present study the mean width of gall bladder from lateral sides of broiler from 2nd, 4th and 6th week of age was 0.70 cm, 1.03 and 1.51 cm, respectively. In present study values are higher thenHaffajee, (2000) reported that the mean width ranged from 0.41 to 0.60 cm. Braun and Kruger, (2013)promulgated that width of gallbladder varied from 0.90 cm to 1.8 cm having higher values then present study.

In present study the mean thickness of gall bladder of broiler from 2nd, 4th and 6th week of age was 0.60 cm, 1.04 cm and 1.42 cm, respectively. The higher findings are reported by Clark, (2005) that the thickness of avian gall bladder was 1.50 to 1.70 cm. Present finding are lower than Mobini, (2012) who reported that thickness of gall bladder were in the range of 1.20 to 2.00 cm.

In present study the mean circumference of the gall bladder of broiler from 2nd, 4th and 6th week of age was 1.51 cm, 2.30 cm and 3.12 cm, respectively. These finding are in agreement with Clark, (2005) who reported that the avian gall bladder have a circumference from middle of entire gall bladder was 1.90 to 3.50 cm. Mobini, (2012) stated that circumference of gall bladder were ranged from 1.50 to 4.00 cm. The differences in weight, length, width, thickness and circumference reported by above authors were due to difference in age, breeds, quality of feeds, environment and farming techniques.

As indicated in literature growth is an incredibly complex phenomenon, which involves changes in body form, metabolism, and body processes. The traditionally accepted theory has been that most of the biological effects of growth hormone (GH) are mediated by circulating (endocrine) insulin-like growth factor-I (IGF-I). This dogma was modified when it was discovered that most tissues express IGF-I that can act via an autocrine/paracrine fashion. In addition, both GH and IGF-I had independent effects on various target tissues. Using tissue-specific gene deletion of IGF-I in the liver, it has been shown that circulating IGF-I is predominantly liver-derived but is not essential for normal postnatal growth. Age related growth in liver definitely follow this mechanism so that time related changes occurs in this organ (Andre, 2001).

Breed related factors which influence, weight, length, width, thickness, and circumference of liver exhibits probably as much as 20% variation within a species with respect to geographic locality and time of the nesting season. There is also considerable local variation, irrespective of season and locality, which is related to nutrition and perhaps to an inherited variability (Ricklefs, 1968).

Feed affects growth performance and lipid metabolism in broilers and this definitely influenced the growth of liver and gall bladder. Researchers reported that lipopolysaccharide included feed in birds developed heavier livers, spleens and intestines relative to body weights and higher rectal temperatures and hepatic metallothionein concentrations (Panda, 2000).

As for environmental factor is concerned on body growth and specifically in the study organs, it is speculated that broilers grow in our environment is hot and it is reported that hot environment had significant effect on average daily feed intake (ADFI), average daily gain (ADG) and feed conversion ratio (FCR) (Dale and Long, 1958).

REFERENCES

Altan, O., A. Altan, M. Cabuk and H. Bayraktar.2000. Turk Veternerlik Ve Hayvancilik Dergisi., 24(2): 145-149.

Behzad M.,2013. Histological study of hepatic bile ducts in the common quail (Coturnix). Int. Res. J. of Appli.and Basic Sci. Vol. 4 (5): 1067-1070.

Borges, S.A., J. Ariki, C.L. Martins and V.M. Moraes. 1999. Relação (Na+K-Cl) emdietas de frangos de cortedurante o verão. In: Conferência Apinco de Ciência e Tecnologia Avícolas. Revista Brasileira de Zootecna., 28(2):313-319).

Braun, U. andK. Sonka.2013. Ultrasonography of the spleen, liver, gallbladder, caudal vena cava and portal vein in healthy birds Acta Veterinaria Scandinavica, 55:68.

Caceci, T. 2006.Avian digestive system. Academic Press, Itheca, New York. Pp;1-94.

Clark, F. D. 2005. Normal Birds - A Review of Avian Anatomy. Avian Advise.7:1.

Daghir, N. J. 2008.Poultry Production in Hot Climates, (2nd Ed.) Published by CAB International, Wallinford, Oxfordshire, UK, Pp.387.Damerow, G. 1995. A Guide to Raising Chickens. Storey Books. ISBN 0-88266-897-8.

DeRuiter, M. C., R. E. Poelmann, M. M. Mentink, L. Vaniperen and A. C. Gittenberger Groot. 1993. Early formation of the vascular system in quail embryos. Anat. Rec. 235: 261–274.

Dyce, K., W. O. Sack and G. J .G. Wensing. 2002. Text book of Vet. Anat. W. B. Sounders Co. 94 U.S.A. Pp: 806-811.

Gomez, K. A. and A. A. Gomez. 2000.Statistics for Agriculture Research. John Wiley and Sons, New York.

Gould, W.J. 1992.Liver disease in psittacines. In: Miller, R.E. Current veterinary therapy XI small animal practice. Philadelphia: W.B. Saunders, Pp.1145-1150.

Haffajee M. R. (2000). The avian gallbladder morphology and morphometry by microdissection. Journal of Surgical Radiological Anatomy 22 261- 70.

Hanan, A. R. 2013.Morphological and histological study for liver in local coot birds fulicaatra. J. of Anat. and Histol., Coll. of Vet. Med., Uni. of Basrah .Basrah. Iraq. Bas. J.Vet. Res. 12 (1): 2013.

Hogan, M. C. 2008.Guanaco: Lama guanicoe, Global Twitcher.com, (1st Ed). N. Strömberg.

Homer, B. L. and T. P. Lois. 1923.The Variability in the Gross Body Weight and the Weights of the Liver, Feathers and Blood of 131 Chickens doi: 10.3382/ps.0030011 Poult. Sci., 3 (1):11-14.

Hoppe, P.P. 1999.Poultry International: Asia Pacific Ed., 38(11):52-62.

Ishi, P.V., D.P. Dhande, S.A. Gaikwad and R.B. Jagadale. 2001.Microanatomical studies of the liver in broilers.J of Bombay Vet. Coll. 9 (1/2): 30-33.

Ishi, P.V., D.P. Dhande, M.A. Kumar and R.B. Jagadale. 2000.Macroanatomical studies of the liver in broilers. J of Bombay Vet College . 11. (5/6) : 97-100.

King, A.S. and J. McLelland.1984 (a).Birds their structure and function. Philadelphia: Bailliere Tindall.

King, A.S. and J. Mclelland.1984 (b).Birds their structure and function.(2nd Ed.) Bailliere, Tindall, London. 2 : 9-106.

Latimer, H. B. 1925. The relative postnatal growth of the systems and organs of the chicken. Anat. Rec., 31:233-253.

Longo, F. A., J. F. M. Menten, J. O. B. Sorbara, A. A. Pedroso, A. N. Figueiredo, A. M. C. Racanicci and J. B. Gaiotto. 2003. Effects of different protein sources in the feed of newly hatched chicks on broiler performance. Poult. Sci. 82(Suppl. 1):67.

Lucas, A.M. and E.M. Denington. 1956.Morphology of the chicken liver. Poult. Sci.,35(4):793-806.

Maria, R. S., M. P. Ricciardi, E. Giannessi and A. Coli. 2006.Morphological and histological study of the Ostrich (*Struthiocamelus*) liver and biliary system. Department of Veterinary Anatomy, Biochemistry and Physiology, Vialedelle Piagge 2, 56124, Pisa, Italy.

Maya, S., K. M. Lucy, V. R. Indu, K. Karthiayini and A. Asha. 2012.Microanatomical observations on the gall bladder in kuttanad duck (Anasplatyrynchos domesticus). Sciences Index Copernicus International I. C. Value 6.29 pp. 57-59.

Medlock, E. S. and J. L. Haar. 1983. The liver hemopoietic environment: I. Developing hepatocytes and their role in fetal hemopoiesis. Anat. Rec., 207: 31–41.

Mobini, B. 2012.Microscopic study of the gall bladder of the ChukarPartidge (*Alectorischukar*).Bulg. Jr of Vety. Med., 15(2):73−78.

Monga, S. P., P. Pediaditakis, K. Mule, D. B. Stolz and G. K. Michalopoulos. 2001.Changes in Wnt/h-catenin pathway during regulated growth in rat liver regeneration. Hepato., 33:1098– 1109.

Panda, A. K., M. R. Reddy, S. V. Rao, M. V. and N. K. Praharaj.2000. Growth carcass characteristics, immunocompetence and response to *Escherichia coli* of broilers fed diets with various levels of probiotic. Vol. 64. pp. 152-15.

Peter, M., E. Tumova, R. Rajmon, B. Zuzana and H. Helena. 2012. The influence of restrictive feeding of chickens on the microscopic structure of their liver. Acta Vet. Brno. 81:27–30.

Raloff, J. 2003.Food for Thought: Global Food Trends. Science News Online.http://www.sciencenews.org/view/generic/id/3902/description/Global Food Trends.

Reddy, C.V. 2000.Poultry International: Asia Pacific Ed., 31(1):36-40.

Romer, A. S. and S. T. Parsons. 1977. The Vertebrate Body. Philadelphia, PA: Holt-Saunders International. pp.355.

Sarkarati, F. and Y. Doustar. 2012. The frequency of liver lesions of broilers slaughtered in Tabriz abattoir. Ann. of Biol. Res., 3(7):3439-3443.

Turk, D. E. 1982. The anatomy of the avian digestive tract as related to feed utilization. Poult. Sci.,61(7):1225-1244.

Whitlow, G.G. 2000.Gastrointestinal Anatomy and Physiology. Avian Physiology. (5th ed.), Academic Press, Honoiula Hawaii Pp:299-304 .

Zebisch. K, M. E. K. Junghanns and J. Willuhn.2004. Ultrasound-guided liver biopsy in birds Veterinary Radiology and Ultrasound Vol. 45 (3): pp 241.